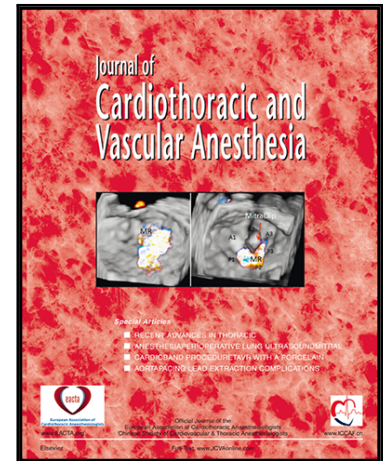


## Journal Pre-proof

Perioperative Echocardiography during the Coronavirus Crisis – considerations in pediatrics and congenital heart disease

John G. Augoustides MD, FASE, FAHA Professor

PII: S1053-0770(20)30381-5  
DOI: <https://doi.org/10.1053/j.jvca.2020.04.022>  
Reference: YJCAN 5869



To appear in: *Journal of Cardiothoracic and Vascular Anesthesia*

Please cite this article as: John G. Augoustides MD, FASE, FAHA Professor , Perioperative Echocardiography during the Coronavirus Crisis – considerations in pediatrics and congenital heart disease, *Journal of Cardiothoracic and Vascular Anesthesia* (2020), doi: <https://doi.org/10.1053/j.jvca.2020.04.022>

This is a PDF file of an article that has undergone enhancements after acceptance, such as the addition of a cover page and metadata, and formatting for readability, but it is not yet the definitive version of record. This version will undergo additional copyediting, typesetting and review before it is published in its final form, but we are providing this version to give early visibility of the article. Please note that, during the production process, errors may be discovered which could affect the content, and all legal disclaimers that apply to the journal pertain.

© 2020 Published by Elsevier Inc.

**EDITORIAL**

**Perioperative Echocardiography during the Coronavirus Crisis – considerations in pediatrics and congenital heart disease**

**John G. Augoustides MD, FASE, FAHA**

Professor

Cardiovascular and Thoracic Section

Department of Anesthesiology and Critical Care

Perelman School of Medicine, University of Pennsylvania,

Philadelphia, Pennsylvania, USA

**e-mail:** yiandoc@hotmail.com

**Conflicts of Interest:** None

**Financial Support:** Institutional

**Corresponding Author**

**John G. T. Augoustides MD, FASE, FAHA**

Professor

Cardiothoracic Section

Anesthesiology and Critical Care

Dulles 680, HUP

3400 Spruce Street

Philadelphia, PA, 19104-4283

**Tel:** (215) 662-7631

**Fax:** (215) 349-8133

**E-mail:** yiandoc@hotmail.com

**Key Words:** echocardiography; coronavirus; viral transmission; safety; aerosolization; pediatrics; personal provider equipment

## **Introduction**

The current coronavirus crisis is now a pandemic, presenting multiple challenges to the conduct and practice of echocardiography, including the risks of infection.<sup>1-3</sup> The management of perioperative echocardiography in suspected and infected pediatric patients requires careful consideration of this infectious risk, including personal protective equipment.<sup>3-4</sup> These significant considerations have recently prompted specific statements for echocardiography in these settings from the American Society of Echocardiography, the British Society of Echocardiography and the Italian Society of Echocardiography and Cardiovascular Imaging.<sup>5-7</sup> The unique considerations for echocardiography in pediatrics and congenital heart disease have now also received due attention.<sup>8</sup>

The purpose of this freestanding editorial is to provide perspectives on this important disease for the perioperative echocardiographic community with respect to pediatric and congenital heart disease patients. The indications, venue, and approaches for imaging will be discussed in these settings to offer a framework to navigate these compelling considerations in pediatric practice. These recommendations will be examined from the perspective of the cardiovascular anesthesiologist and perioperative echocardiographer to encourage best practices in this clinical arena. The provided references can also assist policy leaders in their management of the pandemic at their institutions.

### **1. Consider the Indications for Imaging**

Pediatric echocardiography, including transthoracic, transesophageal, and fetal imaging, has established indications and procedures.<sup>9-10</sup> Based on published appropriate use criteria for

pediatric echocardiography, the indication for an echocardiographic examination is considered appropriate when the expected incremental information, combined with clinical judgment, exceeds the expected risks to a acceptable and reasonable degree.<sup>10-11</sup> Furthermore, an indication for echocardiographic imaging has been classified into one of 3 categories: generally appropriate (as reflected by a median panel score of 7-9); maybe appropriate (as reflected by a median panel score of 4-6); and , rarely appropriate (as reflected by a median panel score of 1-3).<sup>10-12</sup> The goal with this scale of appropriate use criteria has been to minimize echocardiography examinations in pediatric practice for rarely appropriate criteria.<sup>10-12</sup>

With the advent of the coronavirus crisis and the potentially life-threatening risks of infection, the imaging indication in pediatric echocardiography should be carefully screened with a preference for delaying examinations that are either elective or that are rarely appropriate in accordance with institutional practice.<sup>8-12</sup> Emergency examinations in pediatric echocardiography with strong indications therefore have a high priority to proceed. Given that the intensity of the coronavirus crisis is variable and dynamic, the triage of echocardiography examinations must remain agile and responsive to local conditions.<sup>13</sup> This management process should also focus on strict infection control.<sup>1-3</sup>

Fetal echocardiography should also be triaged based on published levels of risk.<sup>14</sup> A fetal echocardiogram for a low-risk patient will typically have a low-risk referral indication in the setting of a normal cardiac screening exam and as such has a low priority for further consideration during the peak of the coronavirus crisis.<sup>8;14</sup> A fetal echocardiogram for a moderate-risk patient will typically be indicated by a moderate-to-high risk referral indication with a gestational age greater than 24 weeks or by confirmed congenital heart disease with a gestational age less than 34 weeks.<sup>8;14</sup> These examinations can typically be rescheduled after the

peak of the crisis has passed.<sup>8</sup> A fetal echocardiogram for high risk patients will typically include an urgent clinical indication, or a moderate-to-high risk referral indication with a gestational age less than 24 weeks, or conformed congenital heart disease with a gestational age above 34 weeks.<sup>8;14</sup> The examinations in this category should be scheduled as soon as possible. The details of this management process have also been fully covered in the provided references and are beyond the scope of this editorial.<sup>8-12; 14</sup>

Transesophageal imaging is considered high-risk since it is associated with viral aerosolization and consequent increased risk of transmission.<sup>15-16</sup> Consequently, the threshold for this imaging modality in pediatric practice should be high during the coronavirus crisis. These examinations have low priority in the setting of a weak indication, borderline clinical impact, or if an alternative imaging modality could be diagnostic according to published consensus and guidelines.<sup>8-12</sup>

## **2. Consider the Venue Selection for Imaging**

Echocardiographic examinations may be possible at the point-of-care by the clinicians already taking care of these children with suspected or proven coronavirus infection.<sup>18-19</sup> This approach is advantageous not only for patient convenience but also for infection control. The final location for an echocardiographic examination will often require thoughtful consideration of the following factors: risk of viral transmission, including pregnant women; monitoring capabilities; and, staffing requirements.<sup>4-8</sup> A complicating factor in pediatric practice is that children with this infection may often be asymptomatic.<sup>20-21</sup> In certain circumstances such as the peak of the coronavirus crisis, it may be reasonable to test new pediatric hospital admissions for this infection to guide the choice of appropriate measures, including infection control.<sup>2-3;8</sup>

In the operating room environment, transesophageal echocardiography is often performed in the setting of a secure airway.<sup>8</sup> This approach to airway management can minimize aerosolization of viral particles and contain viral spread.<sup>21-22</sup> The conduct of transesophageal imaging in the setting of pediatric coronavirus infection should consider current recommendations indexed to institutional practice and the intensity of the coronavirus crisis.<sup>4-8</sup> There may be dedicated probes and machines in this pediatric setting, depending on local factors.<sup>4-8</sup>

### **3. Consider the Approaches to Imaging**

The conduct of the echocardiographic examination in children with suspected or confirmed coronavirus infection could be tailored to address the clinical question.<sup>4-8</sup> The cardiac manifestations of COVID-19 such as pericarditis and myocarditis should be considered during this focused examination.<sup>23</sup> Prolonged echocardiographic examinations should be minimized to limit exposure, given that infectious risks are likely present in asymptomatic children during the crisis phase of COVID-19.<sup>21-24</sup> Consequently, an experienced practitioner should complete the examination in a focused, time-efficient but comprehensive fashion.<sup>4-8</sup> While this strategy may erode the educational environment, the safety of learners and trainees is more important, as outlined clearly by the Accreditation Council for Graduate Medical Education (full details available at [www.acgme.org/covid-19](http://www.acgme.org/covid-19), last accessed April 8<sup>th</sup> 2020).<sup>24</sup>

Apart from the imaging protocol, the conduct of the pediatric echocardiographic examination should take place according to institutional standards for infection control during the crisis, including adequate barrier techniques.<sup>4-8</sup> The degree of personal protective equipment will depend on level of infectious risk as defined by specific testing, institutional protocol and the level of the pandemic at a given hospital.<sup>6-8</sup> Clinical symptoms in infected children may

often be absent, prompting interim strategies such as testing all hospitalized children as needed, or raising the index of suspicion for active infection.

Airborne precautions against viral droplet infection include N-95 masks, N-99 masks as well as powered air purifying respirators.<sup>15-16</sup> Transesophageal imaging in suspected or confirmed coronavirus infection has a heightened risk of viral transmission due to the increased load from viral aerosolization.<sup>4-8</sup> It may be reasonable during the height of the crisis to assume that all children who require transesophageal examinations are positive for the infection. In the setting of a protocol for disease testing, a documented negative test within 48-72 hours may be considered adequate at some institutions to conduct the examination with standard precautions such as eye protection, mask and gloves rather than the enhanced standards with full personal provider equipment.<sup>8</sup> In pediatric patients who do not have known testing results and who have an endotracheal tube prior to arrival in the operating room or interventional suite, the risk of viral transmission from aerosolization is considered low.<sup>4-8</sup>

What about the risks for viral aerosolization in asymptomatic untested children who do not have an endotracheal tube negative and who require transesophageal imaging in the operating room or interventional suite? In this scenario, it is reasonable to plan that the infectious risk is high, assuming that these children may be positive and that endotracheal intubation generates a high load of aerosolized viral particles.<sup>8</sup> In this setting, airway management and probe placement should likely proceed with maximal barrier precautions, including personal provider equipment and consideration for air turnover in the given space.<sup>8</sup> It is also reasonable that the transesophageal probe be placed and positioned by the airway team during aerosol precautions to minimize operators and infectious risks.<sup>4-8</sup> In the setting of children with known

positive infection, full isolation and aerosol precautions should apply not only for the conduct of the echocardiographic examination but also the overall care of those pediatric patients.<sup>4-8; 15-16</sup>

The intensity of the coronavirus crisis at a given institution challenges in many ways not only the imaging protocols and but also the infectious control procedures for pediatric perioperative echocardiography. A further consideration for infection control concerns the appropriate care of echocardiographic equipment (the ‘hardware’) to minimize the risks of viral transmission.<sup>4-8</sup> The relevant probes and machine consoles may be covered with disposable plastic. Depending on institutional circumstances, certain hardware can be specifically designated for imaging of suspected or confirmed pediatric cases of coronavirus infection.<sup>4-8</sup> Although most disinfectant solutions are viricidal, all echocardiographic equipment should be processed thoroughly for the goals of viral clearance and hardware functionality with maximal protection of patients and ultrasound providers.<sup>25-27</sup> Despite the variations in sanitation protocols, these standards should comply with the recommendations from the American Institute for Ultrasound in Medicine to balance infectious risks with imaging performance.<sup>4-8; 25-27</sup>

Education and teaching in pediatric echocardiography are important.<sup>13; 24</sup> During the coronavirus crisis, however, learner wellbeing has a higher priority.<sup>24</sup> In this stressful clinical learning environment, it is reasonable to cancel elective rotations and to restrict trainee exposure.<sup>24</sup> Furthermore, education in echocardiography can be transitioned to distance-based learning, including remote conferencing technology.<sup>24</sup> The protection of echocardiography personnel can be enhanced further by thoughtful assignments for staff with risk factors for severe infection such as advanced age, chronic conditions, immunosuppression, and pregnancy.



### **Conclusions**

The coronavirus pandemic has significantly affected the conduct of pediatric echocardiography in the perioperative setting. Careful consideration of the indications, venues and approaches for echocardiographic imaging will both optimize patient care and infection control during the crisis.

Journal Pre-proof

## **References**

1. He H, Zhao S, Han L, et al. Anesthetic management of patients undergoing aortic dissection repair with suspected severe acute respiratory syndrome Coronavirus-2 infection. *J Cardiothorac Vasc Anesth* 2020 [Epub ahead of print]
2. He Y, Wei J, Bian J, et al. Chinese Society of Anesthesiology expert consensus on anesthetic management of cardiac surgical patients with suspected or confirmed coronavirus disease-2019. *J Cardiothorac Vasc Anesth* 2020 [Epub ahead of print]
3. Li W, Huang J, Guo X, et al. Anesthesia management and perioperative infection control in patients with the novel coronavirus. *J Cardiothorac Vasc Anesth* 2020 {Epub ahead of print}
4. Augoustides JG. Perioperative echocardiography – key considerations during the coronavirus pandemic. *J Cardiothorac Vasc Anesth* 2020 {Epub ahead of print}
5. American Society of Echocardiography. Statement on protection of patients and echocardiography service providers during the 2019 novel coronavirus outbreak. <https://www.asecho.org/wp-content/uploads/2020/03/ASE-COVID-Statement-FINAL-1.pdf>. Full details available at this link (last accessed April 7<sup>th</sup> 2020)
6. British Society of Echocardiography. Clinical guidance regarding provision of echocardiography during the COVID-19 pandemic. Full details available at this link <https://bsecho.org/covid19> (last accessed April 7<sup>th</sup> 2020)
7. Italian Society of Echocardiography and Cardiovascular Imaging. Statement about echocardiography during the COVID-19 pandemic. Full details available at this link (last accessed April 7<sup>th</sup> 2020) <https://www.siec.it/documento-ad-uso-degli-operatori-di-ecografia-cardiovascolare-per-covid-19/>

8. Barker PCA, Lewin MB, Donofrio MT, et al. Specific considerations for pediatric, fetal, and congenital heart disease patients and echocardiography service providers during the 2019 novel coronavirus outbreak: Council on Pediatric and Congenital Heart Disease supplement to the statement of the American Society of Echocardiography (endorsed by the Society of Pediatric Echocardiography and the Fetal Heart Society). Full details available at this link: [https://www.asecho.org/wpcontent/uploads/2020/04/COVID\\_Statement\\_PCHD\\_FINAL.pdf](https://www.asecho.org/wpcontent/uploads/2020/04/COVID_Statement_PCHD_FINAL.pdf) (last accessed April 8<sup>th</sup> 2020)
9. The Intersocietal Accreditation Commission. The IAC standards and guidelines for pediatric echocardiography accreditation. Full details available at this link (last accessed April 8<sup>th</sup> 2020).  
<https://www.intersocietal.org/echo/standards/IACPediatricEchocardiographyStandards2017.pdf>
10. Campbell RM, Douglas PS, Eiden BW, et al.  
ACC/AAP/AHA/ASE/HRS/SCAI/SCCT/SCMR/SOPE 2014 appropriate use criteria for initial transthoracic echocardiography in outpatient echocardiographic cardiology. *J Am Coll Cardiol* 64: 2039-2060, 2014
11. Sachdeva R, Valente AM, Armstrong AK, et al.  
ACC/AHA/HRS/ISACHD/SCAI/SCCT/SCMR/SOPE 2020 appropriate use criteria for multimodality imaging during the follow-up care of patients with congenital heart disease. *J Am Coll Cardiol* 75: 657-703, 2020
12. Sachdeva R, Samai C, Vintcent RN. Pediatric appropriate use criteria for echocardiography: implications for clinical practice. *Pediatrics* 135: e1128-e1130, 2015

13. Al-Ghofaily L, Feinman JW, Augoustides JG. Fellowship training in adult cardiothoracic anesthesiology – navigating the new educational landscape due to the coronavirus crisis *J Cardiothorac Vasc Anesth* 2020 [Epub ahead of print]
14. Donofrio MT, Moon-Grady AJ, Hornberger LK, et al. Diagnosis and management of fetal cardiac disease: a scientific statement from the American Heart Association *Circulation* 129: 2183-2242, 2014
15. Bowdle A, Munoz-Price LS. Preventing infection of patients and healthcare workers should be the new normal in the era of novel coronavirus epidemics. *Anesthesiology* 2020 [Epub ahead of print]
16. Greenland JR, Michelow MD, Wang L, et al. COVID-19 infection – implications for perioperative and critical care physicians. *Anesthesiology* 2020 [Epub ahead of print]
17. Sanders JA, Navas-Blanco JR, Yeldo NS, et al. Incorporating perioperative point-of-care ultrasound as part of the anesthesia residency curriculum, *J Cardiothorac Vasc Anesth* 33: 2414-2418, 2019
18. Beaubien-Soulin W, Denault A, Robillard P. et al. The role of point-of-care ultrasound monitoring in cardiac surgical patients with acute kidney injury. *J Cardiothorac Vasc Anesth* 33: 2781-2796, 2019
19. Dong Y, Mo X, Hu Y, et al. Epidemiological characteristics of 2143 pediatric patients with 2019 coronavirus disease in China. *Pediatrics* 2020 [Epub ahead of print]
20. Cruz A, Zeichner S. COVID-19 in children: initial characterization of the pediatric disease. *Pediatrics* 2020 [Epub ahead of print]
21. Chen X, Liu Y, Gong Y, et al. Perioperative management of patients infected with the novel coronavirus: recommendations from the joint task force of the Chinese Society of

Anesthesiology and the Chinese Association of Anesthesiologists. *Anesthesiology* 2020

[Epub ahead of print]

22. Meng L, Qui H, Wan L, et al. Intubation and ventilation amid the COVID-19 outbreak: Wuhan;s experience. *Anesthesiology* 2020 [Epub ahead of print]
23. Augoustides JG. Cardiovascular consequences and considerations of coronavirus infection – perspectives for the cardiothoracic anesthesiologist and intensivist during the coronavirus crisis. *J Cardiothorac Vasc Anesth* 2020 [Epub ahead of print]
24. Al- Ghofaily L, Feinman JW, Augoustides JG. The fellowship milieu in adult cardiothoracic anesthesiology – fostering psychological wellbeing during the coronavirus crisis. *J Cardiothorac Vasc Anesth* 2020 [Epub ahead of print]
25. American Institute for Ultrasound in Medicine. Guidelines for cleaning and preparing external and internal-use ultrasound transducers between patients and safe handling and use of ultrasound coupling gel. <https://www.aium.org/officialStatements/57> (Full details available at this link - last accessed April 8<sup>th</sup> 2020)
26. American Institute for Ultrasound in Medicine. Quick guide on COVID-19 protections - ultrasound transducers, equipment, and gel. Full details available at this link (last accessed April 8<sup>th</sup> 2020) [https://aium.s3.amazonaws.com/covid19/Covid19\\_Quick\\_Guide\\_UTEG.pdf](https://aium.s3.amazonaws.com/covid19/Covid19_Quick_Guide_UTEG.pdf)
27. American Institute for Ultrasound in Medicine. Quick guide on COVID-19 protections – patients and ultrasound provider protection. Full details available at this link (last accessed April 8<sup>th</sup> 2020) [https://aium.s3.amazonaws.com/covid19/Covid19\\_Quick\\_Guide\\_PUPP.pdf](https://aium.s3.amazonaws.com/covid19/Covid19_Quick_Guide_PUPP.pdf)